



Corneal Refractive Surgery: Coming Full Circle

Photorefractive keratectomy used to be the procedure of choice simply because it was the only show in town. But, more than a decade later, is there good reason to make it our top pick? **By Richard B. Mangan, O.D.**

The concept of reshaping corneal tissue with a laser without thermal collateral damage was first introduced by Stephen L. Trokel, M.D., in 1983. Marguerite B. McDonald, M.D., would later see excimer laser technology through the human clinical trials, with the first human eye being treated by her in 1989.¹

Dr. Trokel's vision of eliminating refractive errors via laser corneal refractive surgery came to fruition in October 1995 when the first excimer laser received FDA approval in the United States for the treatment of mild to moderate myopia. The laser used was the Summit SVS Apex (Summit Technologies, Inc.) and the procedure was photorefractive keratectomy (PRK).

Despite the fact that we had no significant long-term data to offer patients, roughly 70,000 PRK procedures were performed in the United States in 1996.² My own

eyes included. Results early on with excimer laser PRK were excellent.³ During this time, however, clinical trials were already underway in merging the pioneering work of Dr. Trokel and Dr. McDonald with that of Drs. Barraquer and Ruiz.

In 1949, ophthalmologist Jose Ignacio Barraquer, M.D., of Bogota, Columbia, theorized that the addition or subtraction of lamellar tissue could modify the cornea's refractive power. Dr. Barraquer conceptualized and developed a small handheld keratome, similar to a carpenter's plane, which he used to resect layers of corneal tissue. Dr. Barraquer's protégé, Luis Ruiz, M.D., would later expand on his ideas and develop the original automated microkeratome. In 1998, the FDA approved laser in situ keratomileusis (LASIK). The Chiron Automated Corneal Shaper (ACS) and the Bausch + Lomb Hansatome were among the first

modern day microkeratomes utilized during the stromal ablation revolution in the United States.

Finally, we could offer patients a bilateral, pain-free, convenient and immediately effective procedure. Stock volume soared, and laser centers began popping up all over the place.

The result? Procedure volume increased to more than 1,400,000 cases in the year 2000, according to Market Scope. And, through 2006, 24.6 million cases had been performed worldwide.⁴ LASIK had quickly become the most common refractive procedure in the world.⁵

During that time, newer generations of mechanical microkeratomes were being developed and femtosecond laser flap technology was introduced (IntraLase Inc., 2001). More predictable flap creation had arrived and the excitement over LASIK was at an all-time high. While PRK was still used in

cases of inadequate corneal thickness or basement membrane dystrophy, it became an afterthought at most.

In 2005, however, a panel of the world's leading experts in laser refractive surgery, cornea and ocular surface disease convened in Seattle during the American Society of Cataract and Refractive Surgery (ASCRS) Summer Refractive Congress.⁶ Moderated by Richard L. Lindstrom, M.D., this panel of experts gathered to discuss a noted resurgence in advanced surface ablation techniques. The panel offered the following reasons to explain this renewed interest in surface treatments:

- Fewer residual higher-order aberrations, as compared to LASIK.
- Concerns over LASIK flap-related complications.
- Concerns over post-LASIK ectasia.
- Concerns over LASIK's effect on tear film stability.
- Improved wound healing after PRK with mitomycin C (MMC).

In the following pages, we will look closely at these observations from an evidence-based perspective.

PRK May Be Better Suited for Wavefront Technology

Wavefront-guided refractive surgery received FDA approval in August 2002. Up until that

time, traditional ablation profiles addressed second-order aberrations only—notably myopia, hyperopia and astigmatism. However, studies utilizing wavefront aberrometry showed that traditional PRK and LASIK procedures had a tendency to increase higher-order aberrations.^{7,8} LASIK, especially, had been shown to increase coma and spherical-like aberrations in larger myopic treatments.⁹ This provided some explanation as to why patients with postoperative 20/20 vision complained about their quality of vision.

Since the introduction of wavefront-guided ablations, investigators have shown that utilizing a wavefront-guided custom profile reduces higher-order aberrations in eyes that undergo LASIK.¹⁰ However, studies also show that in comparing wavefront-guided PRK to wavefront-guided LASIK, PRK induces statistically fewer higher-order aberrations.¹¹

Colleagues at the Moran Eye Center in Salt Lake City conducted a prospective study comparing wavefront-guided PRK and wavefront-guided LASIK; one of the outcome measures being higher-order aberrations (HOAs).¹² Some 104 eyes received custom PRK, and 104 eyes received custom LASIK. All were treated with Visx Star 4 IR Customvue platform.

Post-treatment wavefront analysis showed that the PRK-treated eyes had fewer residual HOAs (coma,

trefoil and spherical aberration) when compared to the LASIK-treated eyes. At six months post-op, the root mean square (RMS, or sum total of higher-order aberrations) for the PRK group was 0.45 μ m (+/- 0.13 μ m), representing a factor increase of 1.29. The LASIK group had an RMS of 0.59 μ m (+/- 0.22 μ m), representing a factor increase of 1.84.

PRK Eliminates Concern Over Flap-Related Complications

While no refractive procedure is without the risk of intra- or postoperative complications, flap-related complications can be significant. With recent advancements in microkeratome technology, as well as the introduction of femtosecond flaps, intraoperative complications, such as buttonhole flaps and free caps, are at an all-time low. Nonetheless, flap complications still occur.

A study out of Hong Kong assessed the complication rate of sub-Bowman's keratomileusis (SBK) in 3,009 eyes.¹³ The flaps were created with the IntraLase femtosecond laser. Intraoperative complications including flap tear, free cap, bubble escape, and flap folds had occurred at a complication rate of 0.33%. Postoperative flap-related complications occurred at a rate of 0.30% and included diffuse lamellar keratitis (DLK) and epithelial ingrowth. The aggregate peri-surgical flap complication rate in this series was

Release Date: November 2010

Expiration Date: November 30, 2013

Goal Statement: Refractive surgery has come a long way since its modest beginnings. When PRK was approved, clinicians reported excellent results. But, LASIK soon became the procedure of choice and has enjoyed its status ever since. Lately, however, there is renewed interest in surface treatments. For example, some clinicians note fewer higher order aberrations with these treatments, compared to LASIK as well as some complications specific to LASIK

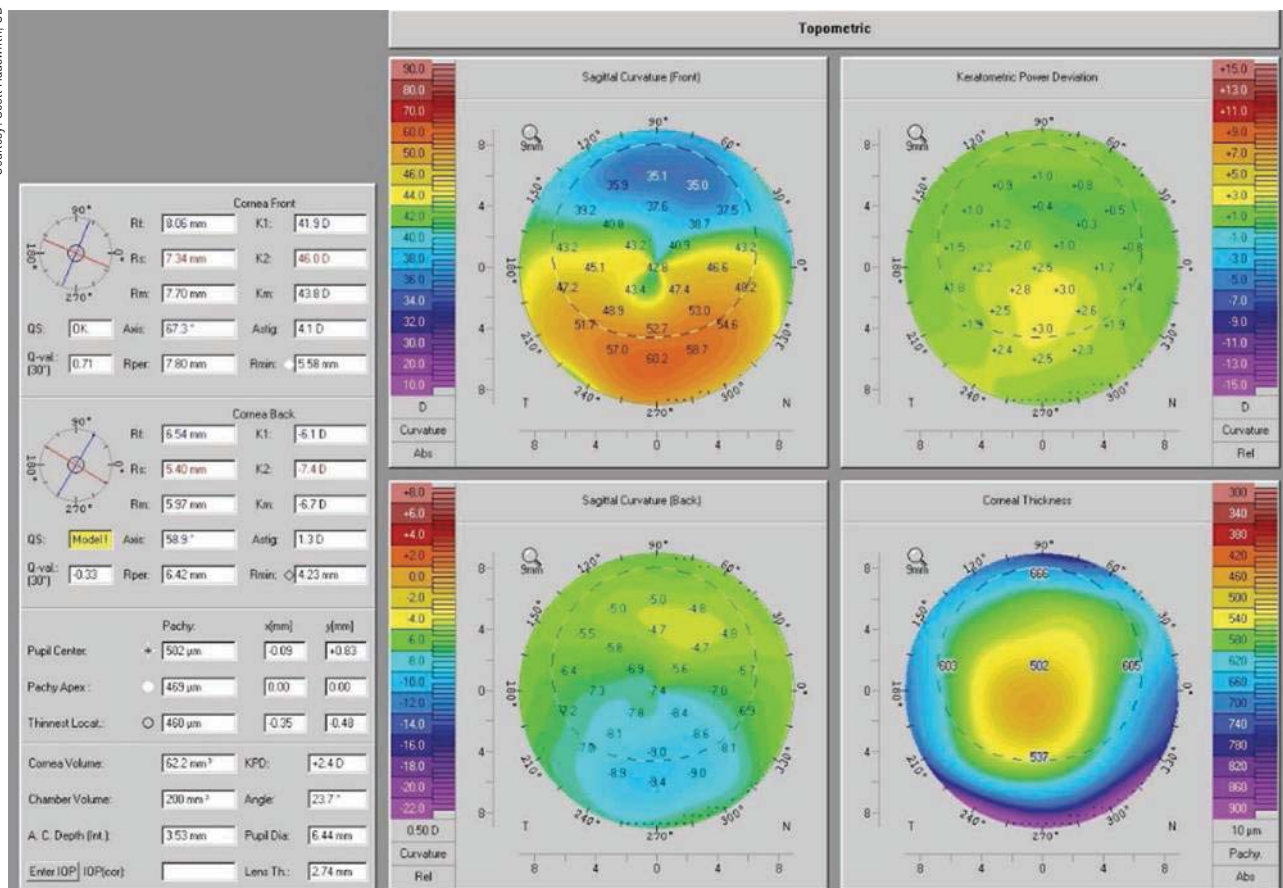
treatments. This paper explores these and other reasons for the resurgence in surface ablation techniques.

Faculty/Editorial Board: Richard Mangan, O.D.

Credit Statement: This course is COPE approved for 2 hours of CE credit: COPE ID: 29708-RS. Check with your local state licensing board to see if this counts toward your CE requirement for relicensure.

Joint-Sponsorship Statement: This continuing education course is joint-sponsored by the Pennsylvania College of Optometry.

Disclosure Statement: Dr. Mangan has no relationships to disclose.



1, 2. The pictures located above and at right are of the right and left eye of the same patient. Scans taken with Pentacam (Oculus).

0.63%.

In comparison, a retrospective analysis of more than 28,500 LASIK procedures that involved either the Chiron Automated Corneal Shaper or Hansatome microkeratomers determined an intraoperative complication rate of 0.302% and included partial flaps, buttonholes, thin or irregular flaps, and free caps.¹⁴

PRK Involves Less Risk of Corneal Ectasia

Iatrogenic corneal ectasia is a serious complication that has been linked to LASIK; and in some cases has led to penetrating keratoplasty.¹⁵⁻¹⁷ The incidence of corneal ectasia after LASIK has been estimated to be 0.2% to 0.66%.^{18,19} While ectasia can also occur with surface ablations, one group's retrospective analysis of 171 cases of ectasia determined that LASIK accounted for 95.9% (n=164) of them.²⁰

Post-LASIK ectasia is most commonly seen within four years of treatment²¹ and is characterized by central to inferior corneal thinning, steepening and irregularity (*figures 1 and 2*). Compound myopic shifts in refractive error are common, as is loss of best-correct-

ed visual acuity.^{22,23}

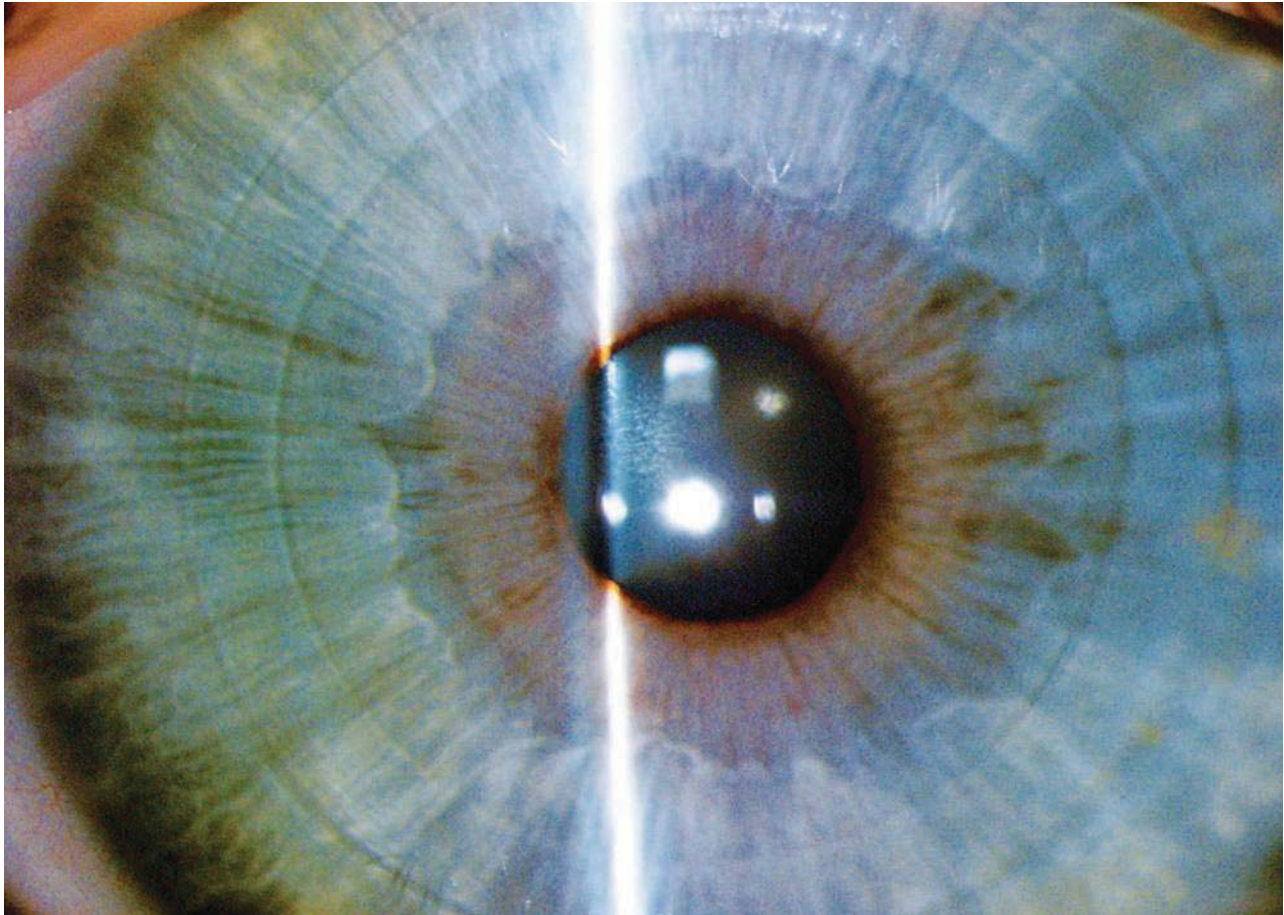
Several risk factors have been identified for post-LASIK ectasia:²⁴

- Thin cornea at baseline.
- Thick corneal flap.
- Low residual stromal bed (RSB).
- Excessive ablation.
- Irregular corneal thickness.
- Diverse ablation rates.
- Pre-existing keratoconus or forme fruste keratoconus
- High intraocular pressure (IOP).

According to one recent study, abnormal topography presents the greatest risk in the development of post-LASIK ectasia, followed (in order) by RSB thickness, age and preoperative corneal thickness.²⁵

Of greater concern to corneal refractive specialists is idiopathic ectasia. This is ectasia that develops despite the absence of preoperative risk factors.²⁶

In 2003, investigators in Chicago reviewed 1,555 potential cases of idiopathic post-LASIK ectasia found via refractive surgery-related internet bulletin boards. Cases were considered idiopathic if the following



3. FLEX procedure: In this picture, you can see the extent of the flap and the edge corresponding to the extracted lenticule (after a few days, you cannot see these edges).

- *Sensory denervation through the severing of the long ciliary nerve branches of the ophthalmic division of the corneal nerve.*²⁷ This, in turn, adversely affects the neuronal-feedback loop responsible for ocular surface homeostasis.

- *Sensory denervation through direct ablation of the subepithelial nerve plexus.*²⁸ Because photoablation begins deeper into the corneal stroma after flap creation, a greater number of corneal nerves and corneal nerve roots are affected.

- *The use of a high-pressure suction device or ring during flap creation.*²⁹⁻³¹ This causes a 40% to 50% reduction in conjunctival goblet cells, resulting in insufficient mucin production.

These factors secondarily lead to a reduction in tear secretion, tear film stability, tear clearance and blink rate. Meanwhile, there is an increase in tear film osmolarity and punctate staining.³²

Also, an estimated 20% to 36% of patients who are asymptomatic prior to LASIK develop chronic dry eye,

lasting a minimum of six months postoperatively.^{33,34} By comparison, studies show that corneal sensations after PRK return to pre-treatment levels by three months post-op, and in some cases as early as one month.^{35,36}

Less Concern Over Haze and Regression Post-PRK with Intraoperative Use of Mitomycin C

The risk of corneal haze and regression after PRK for higher refractive errors has been a longstanding concern for refractive specialists.

Following PRK, the injured epithelial cells release inflammatory mediators and chemotactic factors that attract inflammatory cells (i.e., PMNs and monocytes). Because Bowman's layer is compromised with surface ablations, these inflammatory mediators come into direct contact with the corneal stroma, setting off a wound healing cascade that results in haze formation. LASIK, by comparison, typically leaves the corneal epithelium and Bowman's layer relatively intact, so there is minimal release of inflammatory cytokines, minimal

contact with the corneal stroma, and hence minimal haze formation.

When photorefractive keratectomy was first introduced, mild anterior stromal reticular haze formation was common in treatments for moderate myopia. The postoperative healing response was, in most cases, successfully modulated with the use of topical steroids.³⁷ A small percentage of patients, however, still showed a type III aggressive wound healing response (keratocytic migration and proliferation) that lead to significant haze formation and myopic regression. Mitomycin C, an antibiotic used historically as a systemic chemotherapy/anti-neoplastic agent, has been shown to be very useful as a topical modulating agent that prevents keratocyte proliferation after photorefractive keratectomy.³⁸

In 2006, Iranian investigators looked prospectively at the effect mitomycin C (MMC) had on haze and regression in highly myopic eyes.³⁹ Fifty-four eyes of 28 patients with a mean myopic spherical equivalent of -7.08D (+/- 1.11D) underwent myopic PRK with subsequent MMC 0.02% for two minutes. Using a Hanna grading scale (0 to 4), postoperative haze was evaluated at one week, and at one-, three- and six-months. At one month post-op, just two eyes (3.7%) had grade 0.5 haze, while at three and six months, no haze was reported in any eyes.

Furthermore, all eyes treated achieved 20/40 uncorrected visual acuity, with 77% achieving 20/20. Despite concerns over potential cytotoxicity with MMC, no deleterious effects such as conjunctival chemosis, delayed epithelial migration, edema or melts were noted. The investigators concluded that PRK with MMC was a sound alternative to LASIK for high myopia.

Understanding Corneal Biomechanics

Our knowledge in the area of corneal biomechanics increased dramatically thanks to the work of John Marshall, Ph.D., of King's College, University of London. His work validated many of the aforementioned concerns.

Using X-ray diffraction technology, Dr. Marshall and colleagues demonstrated that the anterior third (150µm) of the central stroma, as well as the peripheral stroma, has the highest density of bridging and interweaving collagen filaments.⁴⁰ The weakest area of the corneal stroma was determined to be the central posterior two-thirds. When a flap is created (whether 100µm or 160µm deep), the cohesive tensile strength of the cornea is permanently weakened.⁴¹ Even though the flap is repositioned at the end of the LASIK procedure, it only contributes approximately 2% of the biomechanical support to the cornea—the rest is left to the thinner residual stromal bed.⁴²

The 2009 International Society of Refractive Surgery survey "U.S. Trends in Refractive Surgery," conducted by Richard Duffey, M.D., and David Leaming, M.D., reflects a growing understanding in corneal biomechanics and the importance of a thicker residual stromal bed postoperatively. Pertinent trends include:

- PRK or surface ablations rose from 14.7% to 15.6% of all laser vision correction volume.
- MMC use for haze prophylaxis in surface ablations is on the rise (92%).
- There is a trend towards thinner flaps, with 49% of surgeons preferring 100µm or less.
- 43% of surgeons measure true flap thickness intra-operatively.
- Nearly two-thirds of surgeons have had at least one case of iatrogenic post-LASIK ectasia. However, this is a downward trend.
- 54% are now leaving a minimum RSB of 275µm microns, compared to 44% choosing 250µm.
- Femtosecond laser use is on the rise (52%).

Is Sub-Bowman's Keratomileusis the Answer?

The idea of thin-flap LASIK (flap thickness between 90µm to 110µm), also known as sub-Bowman's keratomileusis, was put forth by Dr. Marshall as a way of combining the strengths of PRK and LASIK. Whether by mechanical means or laser, we now have the ability to reliably create smoother, thin, planar flaps, thereby allowing SBK to become a practical reality.⁴³⁻⁴⁵ The IntraLase typically creates flaps within +/- 12µm of intended thickness, whereas the LSK-1 and M2 (Moria) flaps were shown to be within +/- 19µm and +/- 24µm, respectively.⁴⁶

In a two-center study, Dan Durrie, M.D., and Stephen Slade, M.D., treated 50 patients, randomizing treatments of dominant eyes between PRK and SBK utilizing the 60Hz IntraLase femtosecond laser.⁴⁷ SBK flaps were designed with an overall diameter of 8.5mm and a thickness of 100µm. All eyes were treated with the LADAR-Vision 4000 and all treatments were wavefront-guided.

Results showed that while visual recovery time was faster with SBK-treated eyes, outcomes at six months were ultimately comparable. The clinical investigators also compared post-treatment corneal hysteresis utilizing the Ocular Response Analyzer (ORA, Reichert) and found that measurements of corneal rigidity were comparable between PRK- and SBK-treated eyes. Another prospective study comparing advanced surface ablation (ASA) to sub-Bowman's keratomileusis was conducted at the Naval Medical Center in San Diego by Steve Schallhorn, M.D., and David Tanzer, M.D.⁴⁸ Two hundred patients were randomized between the

two procedures. Epithelial removal in the ASA group was performed using the Amoils Epithelial Scrubber (Innovative Solutions). In the SBK group, surgeons used the IntraLase femtosecond laser to create flaps at a thickness of 100 μ m. This study showed that visual recovery was faster with SBK, but ultimately outcomes were comparable. Some 88% of eyes in both groups obtained 20/16 or better visual acuity. Additionally, there were no differences between groups in BCVA, photopic contrast acuity, or change in higher-order aberration RMS.

All-in-One Laser Platforms: A Paradigm Shift

While the debate may continue as to the best way to deliver excimer laser technology to the cornea, we may soon find ourselves debating whether or not excimer laser technology has a place in corneal refractive surgery at all.

ReLex (refractive lenticule extraction) is a revolutionary new technique currently being studied in Europe.⁴⁹ Using only femtosecond technology, specifically the Visumax femtosecond laser (Carl Zeiss Meditec, Inc.), a lenticule is created approximately 120 μ m deep from the corneal surface.⁵⁰ This lenticule is removed through a laser incision only 30 to 50 degrees wide (small-incision lenticule extraction, or SMILE) or from under a flap that is laser edged to 250° to 300° (femtosecond lenticule extraction, or FLEX) (figure 3).

Preliminary results look promising, and theoretical advantages of the SMILE procedure include:

- Less risk of flap-related complications (folds, dislocation, ingrowth, etc.).
- Less of an effect on dry eye disease.
- Preserved cohesive tensile strength of the cornea.

- Cost effectiveness in an “all-in-one” laser platform.

Until clinical trials begin here in the United States, we may just have to settle for an already FDA approved “all-in-one” laser procedure that safely and accurately corrects a large range of refractive errors, offers no risk of flap-related complications, has less of an effect on dry eye disease, is better with respect to corneal biomechanics, and does so at half the cost! It makes you wonder why wavefront-guided excimer laser photorefractive keratectomy is just an after-thought for so many of us.

Dr. Mangan is a partner at the Eye Center of Richmond, a multi-specialty co-management practice in Indiana and Ohio. His focus is in the management of ocular surface disease, glaucoma, as well as cataract & refractive surgery. He is chair of the refractive surgery and clinical research committees for the Eye Center of Richmond, and is an adjunct clinical professor at the IU School of Optometry.

1. Excimer Laser Ablation Human Eye Marguerite B. McDonald, MD; Herbert E. Kaufman, MD; Jonathan M. Frantz, MD; Stewart Shofner, MD; Bayardo Salmeron, MD; Stephen D. Klyce, PhD New Orleans, La Arch Ophthalmol. 1989;107(5):641-2.
2. Federal Trade Commission Report. “FTC charges two firms that control the market for laser eye surgery with price fixing conspiracy.” For release: Sept 13, 2006.
3. Shah SS, Kapadia MS, Meisler DM, Wilson SE. Photorefractive keratectomy using the summit SVS Apex laser with or without astigmatic keratotomy. Cornea. 1998 Sep;17(5):508-16.
4. 2006 Market Scope Comprehensive Report in the Global Refractive Market.
5. Sandoval HP, Fernandez de Castro LE, Vroman DT, Solomon KD. Refractive Surgery Survey 2004. J Cataract Refract Surg 2005; 31:221-3.
6. Ocular Surgery News U.S. Edition. Round Table: Safety of advanced surface ablation techniques draws interest. Oct 1, 2005.
7. Oshika T, Klyce SD, Applegate RA, Howland HC, El Danasoury MA. Comparison of corneal wavefront aberrations after photorefractive keratectomy and laser in situ keratomileusis. Am J Ophthalmol. 1999 Jan;127(1):1-7.
8. Yamane N, Miyata K, Samejima T, Hiraoka T, Kiuchi T, Okamoto F, Hirohara Y, Mihashi T, and Oshika T. Ocular Higher-Order Aberrations and Contrast Sensitivity after Conventional Laser In Situ Keratomileusis. Investigative Ophthalmology and Visual Science. 2004;45:3986-90.
9. Oshika T, Miyata K, Tokunaga T, Samejima T, Amano S, Tanaka S, Hirohara Y, Mihashi T, Maeda N, Fujikado T. Higher order wavefront aberrations of cornea and magnitude of refractive correction in laser in situ keratomileusis. Ophthalmology. 2002 Jun;109(6):1154-8.
10. Michael Mrochen, PhD, Maik Kaemmerer, PhD, Theo Seiler, MD, PhD; Clinical results of wavefront-guided laser in situ keratomileusis 3 months after surgery. J Cat Ref Surg. Volume 27, Issue 2, Pages 201-7 (February 2001).
11. Moshirfar M, Schliesser JA, Chang JC, Oberg TJ, Mifflin MD, Townley R, Livingston MK, Kurz CJ; Visual outcomes after wavefront-guided photorefractive keratectomy and wavefront-guided laser in situ keratomileusis: Prospective comparison. J Cataract Refract Surg. 2010 Aug;36(8):1336-43.
12. L. Espandar, MD ; M. D. Mifflin, MD; M. Moshirfar MD, FACS Prospective comparison of visual outcomes after wavefront-guided PRK versus wavefront-guided LASIK. John A. Moran Eye Center, University of Utah, SLC, UT.
13. Chang JS. Complications of sub-Bowman’s keratomileusis with a femtosecond laser in 3009 eyes. J Refract Surg. 2008 Jan;24(1):S97-101.
14. Jacobs JM, Taravella MJ. Incidence of intraoperative flap complications in laser in situ keratomileusis. J Cataract Refract Surg 2002;28:23-8.
15. Amoils SP, Deist MB, Gous P, Amoils PM. Iatrogenic keratectasia after laser in situ keratomileusis for less than -4.0 to -7.0 diopters of myopia. J Cataract Refract Surg 2000;26:967-77.
16. Jabbur NS, Stark WJ, Green WR. Corneal ectasia after laser assisted in situ keratomileusis. Arch Ophthalmol 2001;119: 1714-6.
17. Seitz B, Rozsival P, Feuermannova A, et al. Penetrating keratoplasty for iatrogenic keratoconus after repeat myopic laser in situ keratomileusis: histologic findings and literature review. J Cataract Refract Surg 2003;29: 2217-24.
18. Rad AS, Jabbarvand M, Saifi N. Progressive keratectasia after laser in situ keratomileusis. J Refract Surg 2004;20(suppl): S718-22.
19. Pallikaris IG, Kymionis GD, Astyrakakis NI. Corneal ectasia induced by laser in situ keratomileusis. Vol 27, Issue 11, pgs 1796-1802; Nov 2001.
20. Randleman JB, Woodward M, Lynn MJ, Stulting RD. Risk Assessment for Ectasia after Corneal Refractive Surgery. Ophthalmology 2008; 115:1, Pgs 37-50.
21. Randleman JB, Russell B, Ward MA, Thompson KP, Stulting RD. Risk factors and prognosis for corneal ectasia after LASIK. Ophthalmology 2003;110:267-75.
22. Randleman JB. Post-laser in-situ keratomileusis ectasia: current understanding and future directions. Curr Opin Ophthalmol 2006;17:406-12.
23. Twa MD, Nichols JJ, Joslin CE, et al. Characteristics of corneal ectasia after LASIK for myopia. Cornea 2004;23:447-57.
24. Tabbara KF, Kotb AA. Risk Factors for Corneal Ectasia after LASIK. Ophthalmology 2006; 113:9.
25. Randleman JB, Woodward M, Lynn MJ, Stulting RD. Risk Assessment for Ectasia after Corneal Refractive Surgery. Ophthalmology 2008; 115:1, Pgs 37-50.
26. Klein SR, Epstein RJ, Randleman JB, Stulting RD. Corneal ectasia after laser in situ keratomileusis in patients without apparent preoperative risk factors. Cornea. 2006; 25(4):388-403.
27. Shoja MR, Besharati MR. Dry eye after LASIK for myopia: Incidence and risk factors. Eur J Ophthalmol. 2007;17:1-6.
28. Lee AG. LASIK-induced optic neuropathy. Ophthalmology. 2002;109:817.
29. Albiez JM, Lenton LM, McLennan SG. Effect of laser in situ keratomileusis for hyperopia on tear film and ocular surface. J Refract Surg. 2002;18:113-23.
30. Rodriguez AE, Rodriguez-Prats JL, Hamdi IM, Galal A, Awadalla M, and Alio J. Comparison of Goblet Cell Density after Femtosecond Laser and Mechanical Microkeratome in LASIK. Investigative Ophthalmology & Visual Science, June 2007, Vol. 48, No. 6.
31. Jorge L. Alió, MD, PhD; Alejandra E. Rodríguez, MD; José L. Rodríguez Prats, MD; Ahmed Galal, MD, PhD. Goblet cell study marks a change in approach to dry eye following LASIK. Ocular Surgery News Europe/ASIA-Pacific Edition: 8/1/2006.
32. Toda I, Asano-Kato N, Komai-Hori Y, Tsubota K. Dry eye after laser in situ keratomileusis. Am J Ophthalmol. 2001; 132:1-7.
33. Shoja MR, Besharati MR. Dry eye after LASIK for myopia: Incidence and risk factors. Eur J Ophthalmol 2007;17(1):1-6.
34. DePaiva CS, Chen Z, Koch DD, et al. The incidence and risk factors for developing dry eye after myopic LASIK. Am J Ophthalmol. 2006; 141:438-45.
35. Matsui H, Kumano Y, Zushi I, Yamada T, Matsui T, Nishida T. Corneal sensation after correction of myopia by photorefractive keratectomy and laser in situ keratomileusis. J Cataract Refract Surg.

2001 Mar;27(3):370-3.

36. Pérez-Santonja JJ, Sakla HF, Cardona C, Chipont E, Alió JL. Corneal sensitivity after photorefractive keratectomy and laser in situ keratomileusis for low myopia. *Am J Ophthalmol*. 1999 May;127(5):497-504.
37. Vetrugno M, Maino A, Quaranta GM, Cardia L. The effect of early steroid treatment after PRK on clinical and refractive outcomes. *Acta Ophthalmol Scand*. 2001 Feb;79(1):23-7.
38. Carones F, Vigo L, Scandola A, Vacchini L. Evaluation of the prophylactic use of mitomycin-C to inhibit haze formation after photorefractive keratectomy. *J Cataract Refract Surg* 2002; 28:2088-95.
39. Hashemi H, Taheri MR, Fotouhi A. Prophylactic effects of mitomycin-C on regression and haze formation in photorefractive keratectomy. *Journal of Ophthalmic & Vision Research*, Vol 1, No 1 (2006).
40. Marshall J, Angunawela R, Tengroth J, et al. Wound healing and

- biomechanics of corneal flap creation. Keynote address. XXIV Congress of the ESCRS; September 9-11, 2006; London.
41. Schmack I, Dawson DG, McCarey BE. Cohesive tensile strength of human laser-assisted in situ keratomileusis wounds with histologic, ultrastructural, and clinical correlations. *J Refract Surg*. 2005; 21:433-5.
42. Dawson DG, Kramer TR, Grossniklaus HE, Waring GO III, Edlhauser HF. Histologic, ultrastructural, and immunofluorescent evaluation of human laser-assisted in situ keratomileusis corneal wounds.
43. Lewis JS. Second-generation single use microkeratome: an attractive option for SBK procedures. *Ophthalmology Times* 2010;35(1)26-7.
44. Norden R. Comparison of the One Use-Plus SBK versus the femtosecond laser in sub-Bowman keratomileusis. Paper presented at: the American Society of Cataract and Refractive Surgery annual meeting, April 3-8, 2009; San Francisco, CA.
45. Casado D. SBK with a mechanical microkeratome: Prospective

- clinical study after 1350 eyes. Paper presented at: the European Society of Cataract and Refractive Surgeons annual meeting; September 12-16, 2009; Barcelona, Spain.
46. Talamo JH, Meltzer J, Gardner J. Reproducibility of flap thickness with IntraLase FS and Moria LSK-1 and M2 microkeratomes. *J Refract Surg*. 2006;22(6):556-61.
47. Daniel S, Durrie, MD; Stephen G Slade, MD and John Marshall, PhD. Wavefront-guided Excimer Laser Ablation Using Photorefractive Keratectomy and Sub-Bowman's Keratomileusis: A Contralateral Eye Study. *J Refract Surg*. 2008;24:S77-S84.
48. Schallhorn S. Advanced Surface Ablation, Sub-Bowman's keratomileusis equally safe, effective 6 months post-op. *Ophthalmology times Meeting E-News* Nov. 9, 2007.
49. Doane JF. Visumax Femtosecond Laser Offers an All-in-One Refractive Procedure. *Cat & Refract Surgery Today* (March 2010)
50. Personal conversation with Jesper Hjortdal, Professor, MD, PhD; Department of Ophthalmology, Aarhus University Hospital; Denmark.

OSC QUIZ

You can obtain transcript-quality continuing education credit through the Optometric Study Center. Complete the test form (page 118), and return it with the \$35 fee to: Optometric CE, P.O. Box 488, Canal Street Station, New York, NY 10013. To be eligible, please return the card within one year of publication.

You can also access the test form and submit your answers and payment via credit card at *Review of Optometry Online*, www.revoptom.com.

You must achieve a score of 70 or higher to receive credit. Allow eight to 10 weeks for processing. For each Optometric Study Center course you pass, you earn 2 hours of transcript-quality credit from Pennsylvania College of Optometry and double credit toward the AOA Optometric Recognition Award—Category 1.

Please check with your state licensing board to see if this approval counts toward your CE requirement for relicensure.

- Which laser was the first excimer laser approved in the U.S. for the treatment of mild to moderate myopia?
 - Bausch + Lomb Technolas.
 - VISX Star.
 - Summit SVS Apex.
 - Nidek EC 5000.
- Microkeratome technology was pioneered by which ophthalmologist?
 - Stephen Trokel, M.D.
 - Marguerite McDonald, M.D.
 - Richard Lindstrom, M.D.
 - Jose Barraquer, M.D.
- Proponents for PRK/ASA over LASIK would argue based on the following points except:
 - Flap complications.
 - Comfort and convenience.
 - Ectasia risk.
 - Iatrogenic dry eye.
- Currently, intraoperative flap complications occur approximately what percentage of the time?
 - Less than 1% of the time.
 - 1% to 2% of the time.
 - 5% of the time.
 - 14% of the time.
- Which of the following is considered a second-order aberration?
 - Coma.
 - Trefoil.
 - Astigmatism.
 - Spherical aberration.
- The risk of post-LASIK ectasia with traditional microkeratome flaps has been estimated to occur:
 - Less than 1% of the time.
 - 1% to 2% of the time.
 - 5% of the time.
 - 14% of the time.
- Which is not considered a risk factor for post-LASIK ectasia?
 - A thin RSB (residual stromal bed).
 - Pre-existing keratoconus.
 - Race.
 - High IOP.
- Iatrogenic dry eye post-LASIK, lasting six months or longer, has been estimated to occur in what percentage of patients?
 - 0 to 20%
 - 20% to 40%
 - 40% to 60%
 - 60% to 80%
- As compared to PRK, which of the following has not been implicated as a cause for iatrogenic dry eye after LASIK?
 - Sensory denervation.
 - Goblet cell loss.
 - Deeper ablation depth.
 - Use of MMC.
- Biomechanically, the weakest part of the corneal stroma is:
 - The central anterior third.
 - The central posterior two-thirds.
 - The peripheral edges.
 - The 12 o'clock limbal position.
- Haze and regression are more likely to occur after which corneal refractive procedure for high myopia?
 - LASIK.
 - SBK.
 - PRK with MMC.
 - PRK.
- The LASIK flap, once repositioned, provides what percentage of biomechanical support to the cornea?
 - 2%.
 - 20%.
 - 98%.
 - 100%.
- Which of the following was NOT an accurate trend outlined in the 2009 ISRS survey "U.S. Trends in Refractive Surgery"?
 - Post-LASIK ectasia is on the rise.
 - Femtosecond laser use is on the rise.
 - PRK or surface ablations are on the rise.
 - MMC use in surface ablations is on the rise.